

# Neurorehabilitation and Neural Repair

<http://nnr.sagepub.com>

---

## **Motor Recovery and Cortical Reorganization after Constraint-Induced Movement Therapy in Stroke Patients: A Preliminary Study**

Judith D. Schaechter, Eduard Kraft, Timothy S. Hilliard, Rick M. Dijkhuizen, Thomas Benner, Seth P. Finklestein, Bruce R. Rosen and Steven C. Cramer

*Neurorehabil Neural Repair* 2002; 16; 326

DOI: 10.1177/154596830201600403

The online version of this article can be found at:  
<http://nnr.sagepub.com/cgi/content/abstract/16/4/326>

---

Published by:



<http://www.sagepublications.com>

On behalf of:



[American Society of Neurorehabilitation](#)

**Additional services and information for *Neurorehabilitation and Neural Repair* can be found at:**

**Email Alerts:** <http://nnr.sagepub.com/cgi/alerts>

**Subscriptions:** <http://nnr.sagepub.com/subscriptions>

**Reprints:** <http://www.sagepub.com/journalsReprints.nav>

**Permissions:** <http://www.sagepub.com/journalsPermissions.nav>

**Citations** <http://nnr.sagepub.com/cgi/content/refs/16/4/326>

# Motor Recovery and Cortical Reorganization after Constraint-Induced Movement Therapy in Stroke Patients: A Preliminary Study

Judith D. Schaechter, Eduard Kraft, Timothy S. Hilliard, Rick M. Dijkhuizen, Thomas Benner, Seth P. Finklestein, Bruce R. Rosen, and Steven C. Cramer

*Constraint-induced movement therapy (CIMT) is a physical rehabilitation regime that has been previously shown to improve motor function in chronic hemiparetic stroke patients. However, the neural mechanisms supporting rehabilitation-induced motor recovery are poorly understood. The goal of this study was to assess motor cortical reorganization after CIMT using functional magnetic resonance imaging (fMRI). In a repeated-measures design, 4 incompletely recovered chronic stroke patients treated with CIMT underwent motor function testing and fMRI. Five age-matched normal subjects were also imaged. A laterality index (LI) was determined from the fMRI data, reflecting the distribution of activation in motor cortices contralateral compared with ipsilateral to the moving hand. Pre-intervention fMRI showed a lower LI during affected hand movement of stroke patients ( $LI = 0.23 \pm 0.07$ ) compared to controls ( $LI$  unaffected patient hand =  $0.65 \pm 0.10$ ;  $LI$  dominant normal hand =  $0.65 \pm 0.11$ ;  $LI$  nondominant normal hand =  $0.69 \pm 0.11$ ;  $P < 0.05$ ) due to trends toward increased ipsilateral motor cortical activation. Motor function testing showed that patients made significant gains in functional use of the stroke-affected upper extremity (detected by the Motor Activity Log) and significant reductions in motor impairment (detected by the Fugl-Meyer Stroke Scale and the Wolf Motor Function Test) immediately after CIMT, and these effects persisted at 6-month follow-up. The behavioral effects of CIMT were associated with a trend toward a reduced LI from pre-intervention to immediately post-intervention ( $LI = -0.01 \pm 0.06$ ;  $P = 0.077$ ) and 6 months post-intervention ( $LI = -0.03 \pm 0.15$ ). Stroke-affected hand movement was not accompanied by mirror move-*

*ments during fMRI, and electromyographic measures of mirror recruitment under simulated fMRI conditions were not correlated with LI values. These data provide preliminary evidence that gains in motor function produced by CIMT in chronic stroke patients may be associated with a shift in laterality of motor cortical activation toward the undamaged hemisphere.*

**Key Words:** Stroke—Hemiparesis—Rehabilitation—Magnetic resonance imaging—Motor cortex.

**H**emiparesis is the most common acute deficit of stroke.<sup>1</sup> Most hemiparetic patients experience some degree of motor recovery within the first 6 months after stroke.<sup>2,3</sup> Post-stroke physical rehabilitation may produce gains in motor function beyond those occurring spontaneously.<sup>4</sup> However, the neural mechanisms mediating rehabilitation-induced motor recovery are poorly understood.

Constraint-induced movement therapy (CIMT) is a physical rehabilitation approach that has been shown to further motor recovery of the affected upper extremity in chronic stroke patients with mild to moderate hemiparesis.<sup>5-7</sup> CIMT involves the intensive motor training of the stroke-affected limb coupled with restricted use of the unaffected limb. Determining the neural changes that underlie motor recovery induced by CIMT would help elucidate the mechanisms by which physical rehabilitation can promote post-stroke motor recovery and may guide the development of new, more efficacious therapies.

Functional magnetic resonance imaging (fMRI) has proved to be a useful tool for evaluating cortical reorganization after stroke. Motor recovery during the early period after stroke has been shown by fMRI to be associated with shifts in the extent of activation in the sensorimotor cortex contralateral relative to that ipsilateral to affected hand movement.<sup>8</sup> In patients later after stroke, fMRI has

From the Massachusetts General Hospital–NMR Center, Department of Radiology, Charlestown, MA (JDS, RMD, TB, BRR); the University of Ulm Medical School, Ulm, Germany (EK); Northeastern University, Department of Physical Therapy, Boston (TSH); Massachusetts General Hospital, Department of Neurology, Boston (SPF); and the University of Washington, Department of Neurology, Seattle, WA (SCC).

Address correspondence and reprint requests to Judith D. Schaechter, PhD, PT, Massachusetts General Hospital–NMR Center, 13th Street, Building 149, Room 2301, Charlestown, MA 02129. E-mail: judith@nmr.mgh.harvard.edu.

Schaechter JD, Kraft E, Hilliard TS, et al. Motor recovery and cortical reorganization after constraint-induced movement therapy in stroke patients: a preliminary study. *Neurorehabil Neural Repair* 2002; 16:000–000.

**Table 1.** Demographic and Stroke-Related Data for Stroke Patients

Stroke Patient Number	Age (years)	Gender	Infarct Location	Side of Hemiparesis	Time Post-Stroke (months)
1	36	Female	Left internal capsule	Right	11
2	77	Male	Left pons	Right	20
3	55	Male	Left frontal cortex	Right	12
4	59	Male	Right parietal cortex	Left	7

revealed that affected hand movement is associated with a posterior shift in the center of activation in contralateral sensorimotor cortex<sup>9</sup> and increased activation in ipsilateral sensorimotor cortex, ipsilateral premotor cortex (PMC), bilateral supplementary motor area (SMA), and the peri-infarct region in cases of cortical stroke.<sup>10,11</sup>

A recent pilot study by Levy et al. applied fMRI before and after CIMT in 2 cortical stroke patients.<sup>12</sup> This study found that gains in motor function of the stroke-affected upper extremity after CIMT were accompanied by increased activation in the peri-infarct region in both patients and bilateral sensorimotor cortices in 1 patient. However, neither patient could fully perform the motor activation task at the pre-intervention fMRI session because of poor hand motor function. Thus, the observed increases in cortical activation observed at the post-intervention fMRI session could have been due to improved performance of the motor activation task.

The goal of the current study was to evaluate cortical reorganization associated with motor recovery produced by CIMT using fMRI. We addressed our concern of a possible contribution of performance differences to changes in cortical activation after CIMT by (1) enrolling selected patients who could perform the fMRI motor activation task at study entry and (2) controlling task performance parameters over time. We elected to focus on assessing reorganization in motor cortical areas because activation changes in these areas have been previously shown to relate to motor recovery after stroke.

## SUBJECTS AND METHODS

### Subjects

Entry criteria for stroke patients were as follows: (1) a single unilateral ischemic stroke  $\geq 6$  months earlier that caused acute hemiplegia or severe hemiparesis that included the loss of individuated finger movement; (2) the ability to perform the

motor task used during fMRI (0.5 Hz, 4-finger flexion and extension; see below) with  $\geq 50\%$  of full normal active range of motion at the metacarpophalangeal and interphalangeal joints of the 4 fingers of the affected hand; (3) affected upper extremity motor status and neuropsychological status compatible with being able to competently participate in CIMT and related testing, as described previously;<sup>5-7</sup> and (4) premorbid right-hand dominance.<sup>13</sup> Table 1 gives the demographic and stroke-related data of the 4 stroke patients enrolled in this study (mean age =  $57 \pm 17$  years). Five normal subjects (mean age =  $57 \pm 13$  years; range 40 to 71 years; 3 female) each with normal neurological examination, no history of stroke, and right-hand dominance<sup>13</sup> served as controls. Written informed consent was obtained from all subjects, as approved by the local institutional review board.

### Study Protocol

Consecutive stroke patients participated in 2 weeks of CIMT, preceded and followed by fMRI as well as testing of motor function and surface electromyography (EMG). There were 2 pre-intervention testing sessions (2 weeks prior and 1 day prior) and 3 post-intervention testing sessions (immediately after [within 24 hours], 2 weeks after, and 6 months after), with the exceptions of no fMRI 2 weeks post-intervention and no EMG 6 months post-intervention. Each normal control subject participated in a single fMRI session.

### CIMT

CIMT was performed as previously described.<sup>5-7</sup> Briefly, the 2-week CIMT period involved intensive training of the affected upper extremity and restricted use of the unaffected upper extremity. There were 10 training sessions on the 5 weekdays of the 2-week period, each session lasting 4 hours. During these sessions, each patient practiced a set

of tasks (15 to 25) selected on the basis of individual upper extremity motor abilities and deficits. These tasks included gross and fine functional motor skills, such as grasping and using a spoon, and picking up an object with a specified grasp and transporting it to a specified target. Each task was incrementally modified during the training sessions to challenge and improve motor function. Restricted use of the unaffected upper extremity during the 2-week CIMT period was achieved by wearing a resting hand splint during most waking hours.

### Motor Function Testing

Functional use of the stroke-affected upper extremity was evaluated using the Amount of Use Scale of the Motor Activity Log (MAL). This test is a structured interview that evaluates by self-report the amount of use of the stroke-affected upper extremity in 30 common activities of daily living over a specified period of time (scale 0 to 5).<sup>5</sup> Motor impairments of the stroke-affected upper extremity were evaluated by the following tests: (1) maximum grip strength (N) of the affected and unaffected hands using a computerized dynamometer;<sup>14</sup> (2) maximum frequency (Hz) of 4-finger flexion and extension of the affected and unaffected hands using the same apparatus and fixed active range of motion as described below; (3) upper extremity motor section of the Fugl-Meyer Stroke Scale (FMSS) (scale 0 to 66);<sup>15</sup> and (4) a modified version<sup>5</sup> of the timed (s) items of the Wolf Motor Function Test (WMFT)<sup>16</sup> to evaluate the movement duration of the affected and unaffected upper extremities.

Each motor function measure of the stroke-affected upper extremity was converted to percentage of normal function on the basis of either the measure acquired from the stroke-unaffected upper extremity or the standardized test value of normal function.

### Electromyographic Testing

To evaluate whether ipsilateral motor cortical activation might be related to mirror movements, EMG was applied in stroke patients during performance of the fMRI motor task (0.5 Hz, 4-finger flexion and extension; see below) under simulated scanning conditions. Pre-amplified surface electrodes (Biopac Systems, Inc., Santa Barbara, CA)

were positioned bilaterally over the finger flexor and finger extensor muscle groups. EMG data were collected (1000 samples/s) for the entire duration of the motor paradigm, 1 run during voluntary movement of the stroke-affected hand, and 1 run during voluntary movement of the stroke-unaffected hand.

The EMG data were analyzed for mirror recruitment, which we defined as synchronous involuntary activity of contralateral homologous muscles during voluntary unilateral muscle recruitment. First, the data were full-wave rectified and band-pass filtered (20 to 250 Hz). Then, the root mean square (RMS) of contralateral finger flexor and extensor EMG activity coincident with rest and voluntary movement epochs was calculated. Rest EMG activity was calculated by taking the average RMS during all rest epochs. Movement EMG activity was calculated by taking the average RMS during each 2-second flexion and extension phase during all movement epochs. Phase onset was based on visual inspection of the recordings for burst initiation of voluntary finger flexor and extensor muscle activity. Finally, a mirror recruitment index for the contralateral finger flexors and finger extensors was calculated by dividing EMG activity of the contralateral muscle group during rest epochs by that during movement epochs. An index of 1.00 indicates no mirror recruitment, an index < 1.00 indicates mirror recruitment with increased activity of the contralateral muscle group during movement epochs relative to rest epochs, and an index > 1.00 indicates increased activity of contralateral muscle group during rest epochs relative to movement epochs.

### Imaging Protocol

Imaging data were acquired at the Massachusetts General Hospital–NMR Center using a 1.5 T MRI scanner (General Electric Signa modified by Advanced NMR Systems for 2 stroke and 3 control subjects; Siemens Sonata for 2 stroke and 2 control subjects) and a quadrature head coil. Head motion was minimized by a bite bar and stabilizing straps across the arms and chest. For each subject, 4 sets of blood oxygenation level–dependent (BOLD) functional images were collected using a T2\*-weighted gradient-echo, echo planar imaging (EPI) sequence (repetition time [TR] = 2.5 s; echo time [TE] = 50 ms; field of view = 200 × 200 mm<sup>2</sup>; in-plane resolution = 3.125 mm<sup>2</sup>; 20 slices; 7-mm slice thickness; 104 images/slice). Two sets of structural

images were also collected: (1) T1-weighted gradient-echo EPI (TR = 8 s; TE = 39 ms) taken at the same resolution (3.125 mm<sup>2</sup>) and in plane with the functional images and (2) T1-weighted gradient-echo conventional images (TR = 500 ms; TE = 12 ms) taken at high resolution (0.78 mm<sup>2</sup>) and in plane with the functional images. Slices were oriented parallel to the line connecting the anterior commissure to the posterior commissure and covered the cerebral hemispheres and the superior three quarters of the cerebellum. For each stroke patient, slice positioning applied at the 1st scanning session was used to fine-tune positioning at all subsequent scanning sessions.

During functional imaging, a boxcar function was used with 7 × 20 second rest epochs and 6 × 20 second movement epochs. The motor task was flexion and extension of the 4 fingers in unison. To standardize the kinematics of this motor task, we stabilized the shoulders in the neutral position and the elbows in slight flexion (~15°) with straps. Further, we used a plastic apparatus that stabilized the forearms and wrists in the neutral position and the thumbs in slight flexion and abduction. This apparatus also fixed the maximum excursion through which the 4 fingers actively flexed and extended. For normal control subjects, maximum excursion of the 4 fingers was set at full flexion and extension at the metacarpophalangeal and interphalangeal joints. For patients, maximum excursion of the stroke-affected fingers was set on the basis of the available active range of motion; this was ≥ 50% of full normal active range of motion in all patients. Maximum excursion of the stroke-unaffected fingers was set to match that determined for the stroke-affected fingers. This fixed range of motion was determined at the 1st scanning session for each subject and was applied unchanged at all subsequent scanning sessions.

During each of 4 functional runs, subjects performed the motor task unilaterally, alternating between right (runs 1 and 3) and left (runs 2 and 4) hand performance. Auditory cues were delivered pneumatically to a headset worn by each subject. Stimulus presentation software (MacStim version 2.0) was used to generate a metronome beep at 0.5 Hz throughout each functional run, and “go” and “stop” verbal cues to trigger movement and rest epochs, respectively. The 0.5-Hz beep was used to pace the motor task during movement epochs. Prior to each functional run, subjects were instructed to keep their eyes closed. All subjects were trained prior to each scanning session to accurately and consistently perform the hand

motor task. A research investigator standing beside the scanning bed visually monitored hand motor performance and possible unintended movements, including mirror movements of the contralateral hand.

Image processing and analysis were performed on Sun SPARC workstations using software developed at the Massachusetts General Hospital–NMR Center. The raw images were motion corrected,<sup>17</sup> BOLD signals were drift corrected and intensity normalized, and the 2 functional runs collected for movement of the right and left hands were averaged. Statistical activation maps were generated voxel by voxel using Student’s *t* test, contrasting images acquired during rest epochs with those acquired during movement epochs. The boxcar function was shifted 5 seconds (2 × TR) to account for the delay between neuronal activity and increased cerebral blood flow.<sup>18</sup> The statistical activation maps were registered with the corresponding structural images. Data sets with excessive motion artifact, defined as those yielding statistical activation maps ( $P < 0.001$ ) with spuriously activated voxels throughout the brain volume or at least one quarter of the brain’s circumference, were eliminated from further analysis.

The quantification of activation in motor cortical areas was conducted by a region-of-interest (ROI) analysis. For each subject, the structural scans were used to outline 3 bilateral ROIs on the basis of anatomic landmarks:<sup>19,20</sup> primary motor cortex (M1), PMC, and SMA. The M1 encompassed the posterior half of the precentral gyrus and extended posteriorly midway into the central sulcus. The PMC was taken as the anterior half of the precentral gyrus and extended just rostral of the precentral sulcus. The SMA was taken as the medial cortex superior to the cingulate gyrus, anterior to the mid-precentral gyrus, and extended just rostral of the vertical anterior commissure line. Voxels within these ROIs that met the following criteria were considered activated: (1) significant difference ( $P < 0.001$ , Student’s *t* test, uncorrected) in BOLD signal intensity during rest compared with movement conditions; (2) BOLD signal intensity change < 5%, to exclude voxels with signal coming from draining veins;<sup>21</sup> and (3) clustered with another significantly activated voxel, as a means of correcting for multiple comparisons.<sup>22,23</sup>

The extent of activation in each ROI was determined by counting the number of activated voxels. On the basis of these counts, a laterality index (LI) was calculated to provide an estimate of the relative hemispheric activation in motor cortices.<sup>10</sup> This

index was defined as  $[(cM1 + cPMC + cSMA) - (iM1 + iPMC + iSMA)] / [(cM1 + cPMC + cSMA) + (iM1 + iPMC + iSMA)]$ , where c = contralateral and i = ipsilateral. LI values ranged from +1, indicating that all motor cortical activation occurred in the hemisphere contralateral to the moving hand, to -1, indicating that all motor cortical activation occurred in the hemisphere ipsilateral to the moving hand.

To further examine cortical reorganization after CIMT, we quantified the magnitude of activation in contralateral M1 of stroke patients. We elected to focus on this cortical area because previous transcranial magnetic stimulation (TMS) studies have shown that motor gains after CIMT in chronic stroke patients are associated with a change in contralateral M1 excitability.<sup>24,25</sup> We determined the mean percentage BOLD signal intensity change in M1 contralateral to hand movement for all activated voxels and for the most significantly activated cluster of voxels (defined as the 4 contiguous in-plane voxels with the highest mean significance).

### Statistical Analysis

StatView (version 4.5) and SuperANOVA (version 1.11) were used for statistical procedures. Paired *t* tests were used to compare measures acquired from stroke patients at 2 testing sessions. Repeated-measures analysis of variance (ANOVA) tests with 1 within-subjects factor (side of hand movement) and 1 between-subjects factor (subject group) were used to examine an interaction effect on brain activation. If a significant interaction was detected, paired and unpaired *t* tests were used appropriately to test for differences between means. Repeated-measures ANOVA tests with planned comparisons of means were used to compare motor function testing measures in stroke patients over the study period. The Pearson product-moment correlation coefficient was used to examine correlations. *P* values of < 0.05 were considered significant. Data are presented as group means  $\pm$  standard error of the mean.

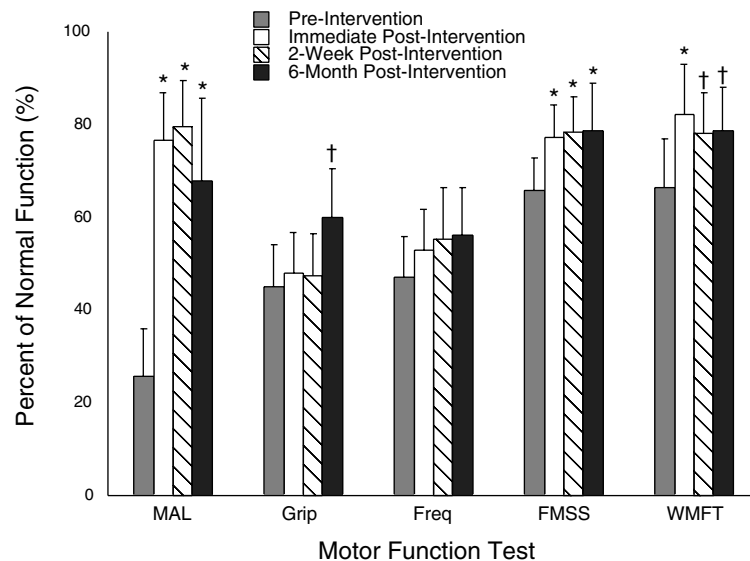
## RESULTS

### Motor Function

Figure 1 presents the results of motor function testing in stroke patients over the course of the study. Motor function test scores were not significantly different at the 2 pre-intervention sessions

and were therefore averaged. Patient 2 was not available for testing at 6 months post-intervention. Pre-intervention, there was markedly reduced use of the affected upper extremity in functional activities (measured by the MAL) and moderate upper extremity motor impairment (measured by grip strength, frequency of 4-finger flexion and extension, FMSS, and WMFT). MAL scores significantly increased from pre-intervention to immediately post-intervention ( $P < 0.01$ ). This behavioral effect was retained on a group basis at 2 weeks post-intervention ( $P < 0.01$ ) and at 6 months post-intervention ( $P < 0.01$ ) compared to pre-intervention. However, 1 stroke patient (patient 4) showed little retention of this behavioral effect at the 6-month follow-up testing session compared to earlier post-intervention testing sessions (MAL pre-intervention = 28%, immediate post-intervention = 62%, 2-week post-intervention = 65%, 6-month post-intervention = 39%). Scores on the FMSS significantly increased from pre-intervention to immediately post-intervention ( $P < 0.01$ ); this effect was retained at the 2-week post-intervention ( $P < 0.01$ ) and 6-month post-intervention ( $P < 0.01$ ) testing sessions. Performance on the WMFT significantly improved from pre-intervention to immediately post-intervention ( $P < 0.01$ ); this effect was slightly reduced but still significant at the 2-week post-intervention ( $P < 0.05$ ) and 6-month post-intervention ( $P < 0.05$ ) testing sessions. Grip strength was significantly increased at 6 months post-intervention compared to pre-intervention ( $P < 0.05$ ), but not at earlier testing sessions. There was no significant change in the frequency of 4-finger flexion and extension from pre-intervention to any post-intervention testing session.

EMG testing in stroke patients showed no difference in the mirror recruitment index during affected or unaffected hand movement at the 2 pre-intervention and 2 post-intervention sessions. Therefore, mirror recruitment index values were averaged over the 2 respective sessions. Pre-intervention, there was no difference in mirror recruitment of contralateral finger flexors or extensors during voluntary movement of the affected hand compared to the unaffected hand (mirror recruitment index affected finger flexion =  $1.01 \pm 0.01$ ; unaffected finger flexion =  $1.00 \pm 0.01$ ; affected finger extension =  $0.88 \pm 0.07$ ; unaffected finger extension =  $0.94 \pm 0.04$ ). Post-intervention, there was also no difference in mirror recruitment of contralateral finger flexors or extensors during voluntary movement of the affected hand compared to the unaffected hand (affected finger flex-



**Figure 1.** Upper extremity motor function in stroke patients over the study period. The Motor Activity Log evaluates functional use of the stroke-affected limb. The other tests evaluate aspects of stroke-affected limb motor impairment. \* $P < 0.01$ , † $P < 0.05$  compared with preintervention.

ion =  $0.97 \pm 0.03$ ; unaffected finger flexion =  $1.00 \pm 0.01$ ; affected finger extension =  $0.97 \pm 0.05$ ; unaffected finger extension =  $0.95 \pm 0.04$ ).

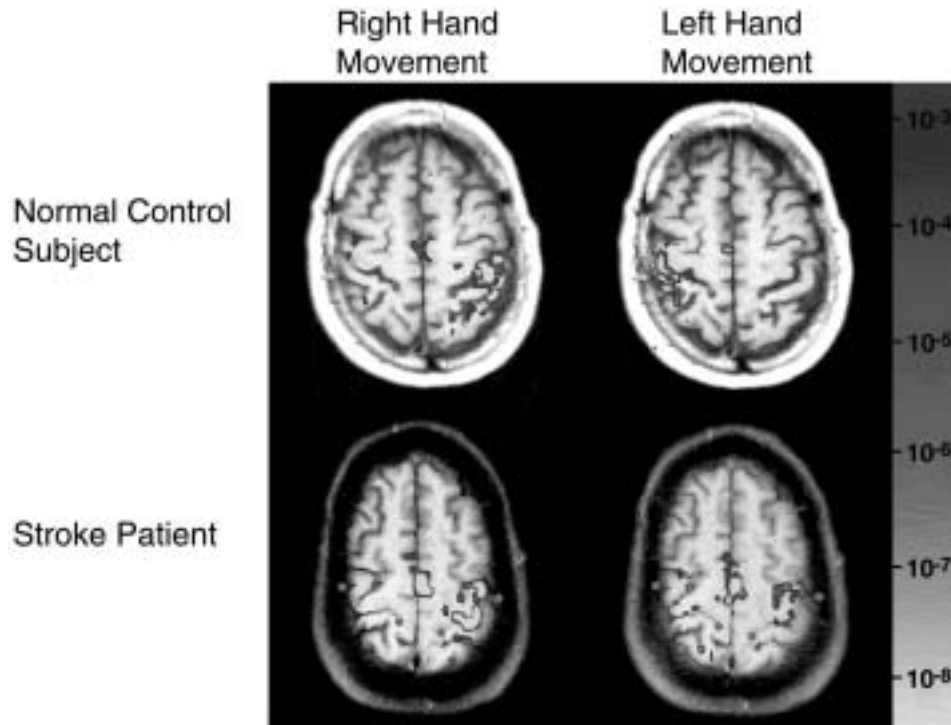
## fMRI

All subjects accurately and consistently performed the hand motor task at each scanning session. No subject exhibited unintended mirror movements of the contralateral hand during volitional unilateral motor task performance at any scanning session. The fMRI data sets acquired from patient 3 at the 1st pre-intervention scanning session and patient 2 during affected hand movement at the immediate post-intervention scanning session were uninterpretable because of excessive head motion and therefore not included in subsequent analysis. Patient 2 was also not available for testing at the 6-month follow-up.

Activation during the movement of either hand of normal control subjects or the unaffected hand of stroke patients was predominantly in the contralateral hemisphere (i.e., M1, PMC, SMA, and somatosensory cortex) and ipsilateral cerebellum; more modest activation was variably observed in these cortical areas of the ipsilateral hemisphere. Before initiating CIMT, activation during stroke-affected hand movement resulted in activation in these same brain regions, although activation in the ipsilateral hemisphere was typically increased. Further, contralateral M1 activation was decreased in the 2 cortical stroke patients and increased in the 2 subcortical stroke patients during affected hand movement compared to unaffected hand

movement. Figure 2 is an example of cortical activation patterns in a normal control subject and a stroke patient pre-intervention (cortical stroke, patient 4).

Table 2 presents quantitative results of the extent of activation in motor cortical ROIs, in number of voxels, during motor task performance in normal control subjects and stroke patients pre-intervention and the resultant LIs. At the 2 pre-intervention fMRI sessions in stroke patients, there was no significant difference in the extent of activation in any ROI during affected or unaffected hand movement; therefore, average values for each patient were determined. There was a significant interaction effect between subject group and side of hand movement on ipsilateral M1 activation ( $P < 0.05$ ). Further analysis revealed that there were trends toward increased ipsilateral M1 activation during stroke-affected hand movement compared to movement of the stroke-unaffected hand ( $P = 0.08$ ) as well as the dominant ( $P = 0.17$ ) and nondominant ( $P = 0.10$ ) hands of normal control subjects. There was a nearly significant interaction effect between subject group and side of hand movement on ipsilateral SMA activation ( $P = 0.06$ ). There was a significant interaction effect between subject group and side of hand movement on LI ( $P < 0.05$ ), with further analysis revealing a significant decrease in LI during stroke-affected hand movement compared to movement of the stroke-unaffected hand and either hand of normal control subjects ( $P < 0.05$ ; Fig. 3). There was no correlation between the pre-intervention LI and mirror recruitment index during affected or unaffected hand movement in stroke patients.



**Figure 2.** Example of cortical activation patterns during performance of the motor task (4-finger flexion and extension, 0.5 Hz) in a normal control subject and a stroke patient preintervention (patient 4) detected by functional magnetic resonance imaging. This patient had a right parietal cortex stroke (not visualized here) and left-hand paresis. Activation during movement of either hand of the normal control subject or the right hand of the stroke patient shows activation predominantly in the contralateral hemisphere. Activation during left-hand movement of the stroke patient shows little activation in the contralateral hemisphere and more extensive activation in the ipsilateral hemisphere. Images are in the axial plane and in radiological co-vention (i.e., the left side of the image is the right hemisphere), with the color-coded statistical activation maps ( $P$  values, Student's  $t$  test) registered on top of the T1-weighted structural images. Green dots indicate the medial and lateral extent of the central sulcus.

**Table 2.** Motor Cortical Activation in Normal Subjects and Stroke Patients Pre-intervention

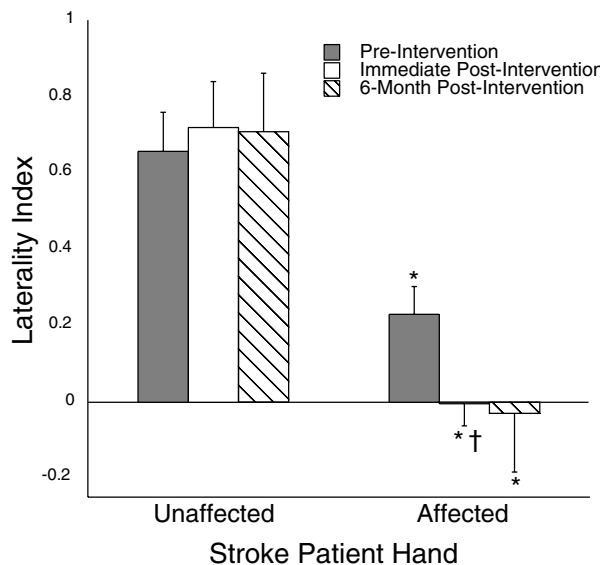
Region of Interest	Normal Control Subjects		Stroke Patients	
	Dominant	Nondominant	Unaffected	Affected
<b>Contralateral</b>				
M1	43.6 ± 6.4	44.6 ± 6.0	35.4 ± 7.3	47.5 ± 20.2
PMC	33.0 ± 7.5	37.8 ± 11.1	22.1 ± 9.6	24.0 ± 11.1
SMA	15.0 ± 5.1	14.6 ± 5.9	27.4 ± 7.4	26.9 ± 10.0
<b>Ipsilateral</b>				
M1	5.0 ± 3.5	4.2 ± 2.8	1.5 ± 0.5	13.3 ± 4.0
PMC	10.6 ± 7.2	9.8 ± 5.3	4.3 ± 1.0	16.5 ± 8.8
SMA	9.0 ± 2.6	9.8 ± 5.7	11.3 ± 5.5	32.8 ± 11.7
LI	0.65 ± 0.11	0.69 ± 0.11	0.66 ± 0.10	0.23 ± 0.07*

M1, primary motor cortex; PMC, premotor cortex; SMA, supplementary motor area; LI, laterality index. Values are the numbers of voxels activated in contralateral and ipsilateral motor cortical areas during movement of the dominant and nondominant hands of normal control subjects and the unaffected and affected hands of stroke patients. LI is the relative volume of activation in contralateral to ipsilateral motor cortical areas (see text). An interaction between subject group and side of hand movement was significant in the ipsilateral M1 ( $P < 0.05$ ) and for the LI ( $P < 0.05$ ) and nearly significant in the ipsilateral SMA ( $P = 0.06$ ).

\* $P < 0.05$  compared with stroke-unaffected hand and either hand of normal control subjects.

Each stroke patient with interpretable data showed a further reduction in the LI during affected hand movement immediately post-intervention compared to pre-intervention, yielding a trend

toward a significant difference ( $P = 0.077$ ; Fig. 3). There was no change in the LI during unaffected hand movement from pre-intervention to immediately post-intervention. The reduced LI during



**Figure 3.** Laterality index (LI) during affected and unaffected hand movement in stroke patients across the study period. LI values were calculated on the basis of volumes of activation in motor cortices (M1, PMC, and SMA) of the contralateral relative to ipsilateral hemispheres detected by functional magnetic resonance imaging (see text). Lower LI values indicate relatively greater activation in ipsilateral motor cortices.

\* $P < 0.05$ , affected hand movement compared with unaffected hand movement. † $P = 0.077$ , affected hand movement immediately postintervention compared with preintervention.

affected hand movement was attributed to different shifts in motor cortical activation among the 3 stroke patients (Fig. 4). In patient 1, the most marked changes were reduced activation in contralateral SMA and contralateral M1. In patient 3, the most marked change was increased activation in ipsilateral SMA. In patient 4, the most marked changes were increased activation in ipsilateral PMC and ipsilateral M1. There was no correlation between post-intervention LI and mirror recruitment indices during affected or unaffected hand movement of stroke patients.

On a group basis at 6 months post-intervention, the LI during stroke-affected hand movement remained lowered compared to pre-intervention (Fig. 3). However, on an individual basis, there were differences in retention of the reduced LI. Two of the 3 available stroke patients showed a retained (patient 1) or exaggerated (patient 3) reduction in the LI in association with retention of increased affected limb use. The LI of patient 4 reverted back to near baseline in association with poor retention of increased affected limb use (measured by the MAL). The LI during unaffected hand movement was unchanged from pre-intervention to 6 months post-intervention.

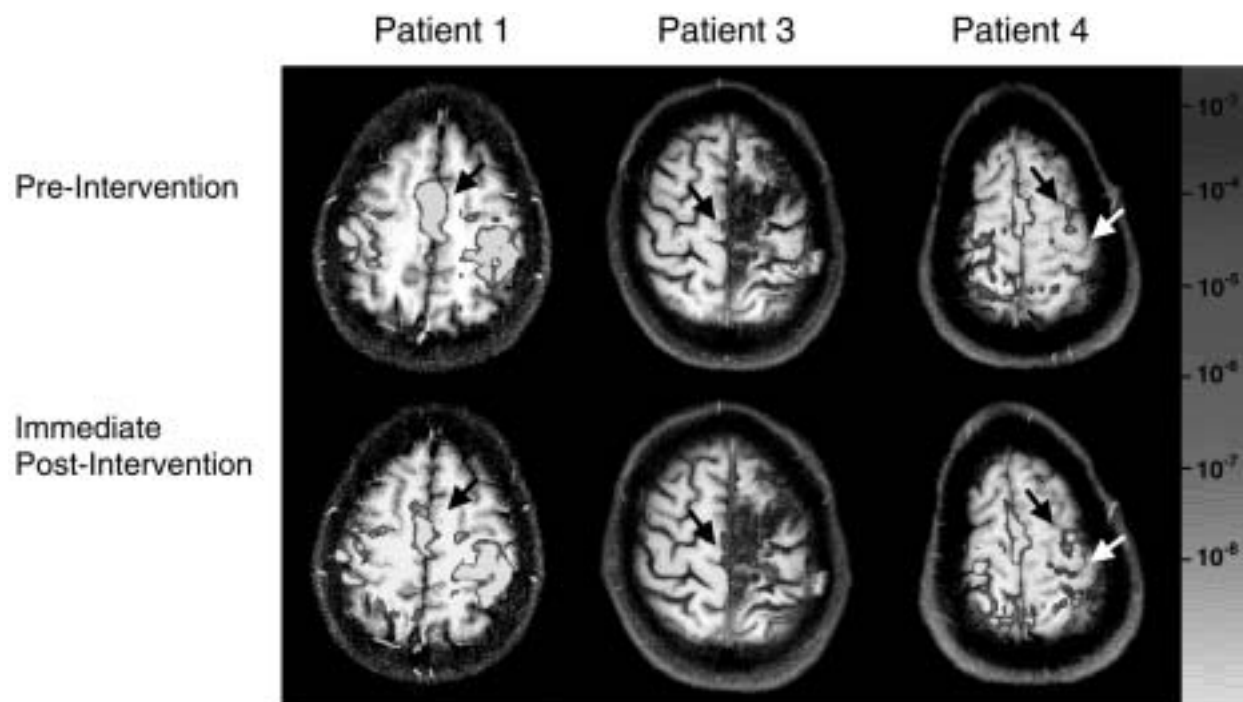
Table 3 presents data on the activation responses in contralateral M1 of stroke patients over the study period. The extent and magnitude of activation in contralateral M1 was unchanged at the 2 pre-intervention sessions during affected and unaffected hand movement. Therefore, these pre-intervention values were averaged within each patient. During movement of the unaffected or affected hand, there was no difference in the extent of activation in contralateral M1 across the 3 fMRI sessions. Further, there was no difference in the magnitude of activation in contralateral M1 during affected and unaffected hand movement when the analysis included all activated voxels or the most significantly activated cluster of voxels.

## DISCUSSION

The novel finding of this study is that each chronic stroke patient participating in a 2-week regimen of CIMT showed gains in motor function of the affected upper extremity that were associated with a relative increase in activation of motor cortices of the undamaged hemisphere during affected hand movement, as demonstrated by fMRI. It is unlikely that this shift in motor cortical laterality was due to motor task performance differences or to unintended mirror movements. These findings suggest that rehabilitative training in chronic stroke patients may promote motor recovery by shifting the balance of motor cortical recruitment toward the undamaged hemisphere.

Motor function of the affected upper extremity in chronic stroke patients improved after CIMT. The most marked effect of CIMT was a self-reported increase in the amount of use of the stroke-affected limb in daily activities (measured by the MAL). The magnitude of this effect was comparable to that found in other studies.<sup>5-7</sup> This effect was paralleled by a reduced level of motor impairment (detected by the FMSS and the WMFT), suggesting that the degree of functional use of the stroke-affected limb may be coupled to its motor ability. Grip strength increased at the 6-month post-intervention testing session, but not at earlier post-intervention sessions. A previous study in chronic hemiparetic patients similarly found a delayed increase in grip strength months after a modified form of CIMT.<sup>16</sup> A delayed increase in grip strength may reflect a long-term effect of increased use of the stroke-affected limb in daily activities.

Pre-intervention fMRI revealed a significantly reduced LI during movement of the stroke-affected hand,



**Figure 4.** Functional magnetic resonance images showing changes in motor cortical activation during affected hand movement in individual stroke patients immediately post-intervention compared to pre-intervention. Each patient showed different patterns of change, although all showed increased activation in motor cortices of the ipsilateral hemisphere relative to the contralateral hemisphere. Patient 1 showed decreased activation in the contralateral supplementary motor area (SMA) (black arrows) and the contralateral primary motor cortex (MI) (when viewed across all slices) during right affected hand movement. Patient 3 showed increased activation in the ipsilateral SMA (black arrows) during right affected hand movement. The area of signal intensity loss is the cortical lesion in this patient. Patient 4 showed increased activation in the ipsilateral premotor cortex (black arrows) and the ipsilateral MI (white arrows) during left affected hand movement.

**Table 3.** Activation in the Contralateral Primary Motor Cortex of Stroke Patients over the Study Period

Hand Movement	fMRI Session	Number of Activated Voxels	SI Change for All Activated Voxels (%)	SI Change for Most Significantly Activated Cluster (%)
Unaffected	Pre-intervention	35.4 ± 7.3	1.49 ± 0.18	2.63 ± 0.40
	Immediate post-intervention	31.8 ± 4.3	1.55 ± 0.12	2.44 ± 0.30
	6-month post-intervention	35.0 ± 8.0	1.52 ± 0.11	2.73 ± 0.40
Affected	Pre-intervention	47.5 ± 20.2	1.48 ± 0.11	2.47 ± 0.28
	Immediate post-intervention	34.3 ± 22.4	1.33 ± 0.08	2.15 ± 0.09
	6-month post-intervention	36.7 ± 13.6	1.52 ± 0.19	2.56 ± 0.10

fMRI, functional magnetic resonance imaging; SI, signal intensity. Values are the extent and magnitude of activation in the contralateral primary motor cortex during unaffected and affected hand movement of stroke patients across the study period. The extent of activation is expressed by the number of activated voxels. The magnitude of activation is expressed as the percent blood oxygenation level-dependent SI change for all activated voxels and for the most significantly activated cluster. No significant changes in extent or magnitude of activation were detected across the study period.

compared to movement of the stroke-unaffected hand and either hand of normal control subjects, due to trends toward increased activation in ipsilateral motor cortices (M1 and SMA). The LI values found in the current study are consistent with those reported by others in partially recovered<sup>8,26</sup> and well-recovered<sup>9,10</sup> stroke patients. Previous func-

tional neuroimaging studies have suggested that the increased ipsilateral motor cortical activation during stroke-affected hand movement might be contributed to by involuntary mirror movements of the unaffected hand.<sup>27,28</sup> The current study found no difference in the EMG-detected mirror recruitment of contralateral finger musculature (mirror

recruitment index) during affected compared with unaffected hand movement in stroke patients. This finding suggests that the reduced LI during stroke-affected hand movement was not due to involuntary mirror movements of the unaffected hand. However, because EMG was conducted offline, we cannot absolutely exclude the possibility that during fMRI, there was greater involuntary mirror recruitment during affected hand movement than unaffected hand movement, perhaps contributing to the increased activation in ipsilateral motor cortical areas during stroke-affected hand movement. This possibility seems unlikely, however, because of the observed lack of correlation between the LI and mirror recruitment index during stroke-affected hand movement and because performance of the motor activation task online was not observably different from that offline.

Immediately after CIMT, all stroke patients in this small sample showed a shift in motor cortical laterality toward the ipsilateral hemisphere in association with improved motor function of the affected limb. On a group basis, this shift in motor cortical laterality after CIMT reached only the level of a nonsignificant trend, likely because of the low statistical power of this pilot study. Further study of a larger cohort of chronic stroke patients is needed to determine whether the observed laterality shift we found is representative of brain reorganization occurring after CIMT in the population. Among the individual patients of the current study, the laterality shift was due to different changes in motor cortical activation. These differences may reflect the relatively heterogeneous group of stroke patients (e.g., time post-stroke, lesion topography, level of motor function) participating in this study. At the 6-month follow-up, the laterality shift was still present in the same 2 of 3 patients who retained improved limb functional use (detected by the MAL) and motor ability (detected by the FMSS and the WMFT). In contrast, the laterality shift was not retained in the 1 patient who had poor retention of increased limb functional use but good retention of limb motor ability. These directional associations suggest that motor cortical laterality may be more strongly linked to stroke-affected limb use than to motor ability. In contrast to the laterality shift associated with the stroke-affected hand after CIMT, there was no concurrent laterality shift associated with the stroke-unaffected hand. This result suggests that repeated testing does not likely account for the laterality shift associated with stroke-affected hand movement after CIMT. Further serial fMRI studies in chronic stroke patients (who do not

receive CIMT) and normal control subjects (who receive CIMT) are needed to evaluate the specificity of the relationship between CIMT-induced motor function gains and laterality shift associated with the stroke-affected limb.

Two previous longitudinal functional neuroimaging studies conducted early after hemiparetic stroke showed shifts in relative hemispheric activation during this phase of motor recovery. Marshall et al. reported a shift in sensorimotor cortical activation toward the damaged hemisphere in association with performance of an activation task that improved across scanning sessions.<sup>8</sup> In contrast, Calautti et al. reported a hemispheric shift toward the undamaged hemisphere in association with performance of an activation task that was unchanged across scanning sessions.<sup>26</sup> Thus, the laterality shift observed in the current study using an activation task that was fixed across all scanning sessions suggests that rehabilitation-induced gains in motor function in chronic stroke patients may be a progression in the cortical processes mediating motor recovery early after stroke.

It is unlikely that the relative increase in ipsilateral motor cortical activation after CIMT observed in the current study was due to a change in stroke-affected hand task performance. Only patients who could perform the fMRI motor activation task at study entry were enrolled. All subjects performed the task as trained at all sessions. Previous functional neuroimaging studies have shown that the movement parameters of rate,<sup>29–31</sup> amplitude,<sup>32</sup> and force<sup>33–36</sup> modulate activation in motor cortices. However, we controlled the rate of motor task performance by metronome pacing and the amplitude of finger motion by an apparatus that fixed the end range of finger flexion and extension. Further, behavioral testing revealed that the maximum frequency of 4-finger flexion and extension did not change over the study period, suggesting that the shift in motor cortical laterality was not likely due to patients performing the fMRI motor activation task with more speed after CIMT. Behavioral testing also revealed that maximum grip strength was not different immediately post-intervention compared to pre-intervention, suggesting that increased force of task performance does not account for the laterality shift immediately after CIMT. Behavioral testing did, however, show improved scores on the FMSS, in part because of reduced synkinesia of the stroke-affected upper extremity. It is possible, therefore, that uncontrolled kinematic details of task performance may have been different during post-intervention fMRI sessions as compared to

pre-intervention sessions, contributing to the laterality shift observed after CIMT.

The motor task used in the current fMRI study may have influenced the results. We previously showed using fMRI that performance of a fine motor task produces a selective activation increase in ipsilateral sensorimotor cortex during movement of a stroke-affected hand compared to a normal control hand yet no activation difference during a gross motor task.<sup>37</sup> These findings suggest that performance of a neurologically challenging motor task during fMRI can differentiate motor cortical status on the basis of relative ipsilateral activation. That there were trends toward increased activation in ipsilateral motor cortices during stroke-affected hand movement before CIMT suggests that the fMRI motor task we used was challenging enough to probe ipsilateral motor cortices and thus may have increased the likelihood of exposing activation changes in motor cortices of the undamaged hemisphere after CIMT.

The current finding of a laterality shift toward ipsilateral motor cortices is distinct from the results of other studies examining neural changes after CIMT. Liepert et al. found using TMS that the excitability of the contralateral motor cortex representation of the stroke-affected hand increased immediately after CIMT.<sup>24,25</sup> In contrast, we found no increase in the extent or magnitude of activation in contralateral M1 after CIMT. The chronicity of stroke in Liepert et al.'s study<sup>25</sup> was greater (mean = ~5 years) than in the current study (mean = ~1 year), which might have influenced the responsiveness of motor cortices to increased stroke-affected limb use. Additionally, that no changes in ipsilateral motor cortex excitability were detected in Liepert et al.'s studies<sup>24,25</sup> may have been because specific experimental maneuvers that are required to elicit ipsilateral motor evoked potentials<sup>38,39</sup> were not applied. Kopp et al., using electroencephalography in stroke patients (chronicity range 4 to 15 years), found that increased use of the affected limb produced by CIMT was associated with a shift in source location associated with affected hand movement within contralateral motor cortex immediately after therapy and into ipsilateral motor cortex 3 months later.<sup>40</sup> Levy et al., using fMRI in 2 patients with cortical strokes (4.5 and 9 months prior), found that both patients showed increased perilesional activation, and 1 patient showed increased bilateral sensorimotor cortex activation, in association with improved performance of the motor activation task.<sup>12</sup> Collectively, these studies raise the possibility that the effect of

CIMT on activity of motor cortices in the damaged and undamaged hemispheres may interact with stroke chronicity, time post-CIMT, and stroke topography. Further, rehabilitation-induced reorganization in motor cortices may be differentially sensitive to detection by various brain-mapping technologies and to experimental conditions.

The laterality shift toward ipsilateral motor cortices observed after CIMT may reflect 1 or more mechanisms. One mechanism may be the amplification of a role that ipsilateral motor cortices normally play in motor control. Studies in normal subjects have shown that ipsilateral motor cortices participate in controlling hand motor function, particularly complex or precise movements.<sup>41-43</sup> Accordingly, the observed laterality shift may reflect the increased participation of ipsilateral motor cortices in controlling stroke-affected limb motor function. Studies in normal subjects have also shown that motor cortices controlling contralateral hand movement concomitantly inhibit motor cortices of the opposite hemisphere, perhaps to prevent potential interference by movement of the other hand.<sup>44,45</sup> Thus, the relative increase in ipsilateral motor cortical activation during stroke-affected hand movement may reflect increased inhibition of unaffected hand movement, providing a neural substrate for the behavioral shift in limb use preference after CIMT. A 2nd mechanism reflected by the laterality shift after CIMT may be the unmasking of existing but previously less active ipsilateral motor pathways, as has been suggested to contribute to spontaneous motor recovery after hemiparetic stroke.<sup>10,11,46,47</sup> A 3rd possible mechanism stems from animal studies showing that experimental stroke induces neurite outgrowth and synaptogenesis in the undamaged motor cortex<sup>48,49</sup> and that post-stroke training that improves motor skill enhances these structural changes.<sup>50,51</sup> These animal studies suggest that CIMT may have enhanced structural reorganization in ipsilateral motor cortices that occurred spontaneously after stroke.

In summary, this study provides preliminary evidence that in selected chronic stroke patients, improved motor function of the affected upper extremity produced by CIMT is associated with increased activation in motor cortices of the undamaged hemisphere, relative to that in the damaged hemisphere. The data suggest that motor cortices of the undamaged hemisphere might be an effective target for new rehabilitative interventions directed at improving motor recovery after stroke. Further studies are required to elucidate the relationship between cortical reorganization and

post-stroke motor recovery facilitated by physical rehabilitation.

## ACKNOWLEDGMENTS

This study was initiated when Judith D. Schaechter was affiliated with Northeastern University and was supported in part by awards (to Dr. Schaechter) from the Research and Development Fund of Northeastern University, the Marion and Jasper Whiting Foundation, and the NeuroRecovery Program of Spaulding Rehabilitation Hospital and Massachusetts General Hospital.

## REFERENCES

- Gresham GE, Duncan PW, Stason WB, et al. *Post-stroke rehabilitation. Clinical practice guideline*. Washington, DC: US Department of Health and Human Services, Public Health Service, Agency for Health Care Policy and Research; 1995.
- Duncan P, Goldstein L, Horner R, Landsman P, Samsa G, Matchar D. Similar motor recovery of upper and lower extremities after stroke. *Stroke* 1994;25:1181–8.
- Nakayama H, Hendrik SJ, Raaschou HO, Olsen TS. Recovery of upper extremity function in stroke patients: the Copenhagen stroke study. *Arch Phys Med Rehabil* 1994;75:394–9.
- Duncan P. Synthesis of intervention trials to improve motor recovery following stroke. *Top Stroke Rehab* 1997;3:1–20.
- Taub E, Miller NE, Novack TA, et al. Technique to improve chronic motor deficit after stroke. *Arch Phys Med Rehabil* 1993;74:347–54.
- Kunkel A, Kopp B, Muller G, et al. Constraint-induced movement therapy for motor recovery in chronic stroke patients. *Arch Phys Med Rehabil* 1999;80:624–8.
- Miltner WHR, Bauder H, Sommer M, Dettmers C, Taub E. Effects of constraint-induced movement therapy on patients with chronic motor deficits after stroke: a replication. *Stroke* 1999;30:586–92.
- Marshall RS, Perera GM, Lazar RM, Krakauer JW, Constantine RC, DeLaPaz RL. Evolution of cortical activation during recovery from corticospinal tract infarction. *Stroke* 2000;31:656–61.
- Pineiro R, Pendlebury S, Johansen-Berg H, Matthews PM. Functional MRI detects posterior shifts in primary sensorimotor cortex activation after stroke: evidence of local adaptive reorganization? *Stroke* 2001;32:1134–9.
- Cramer SC, Nelles G, Benson RR, et al. A functional MRI study of subjects recovered from hemiparetic stroke. *Stroke* 1997;28:2518–27.
- Cao Y, D'Olhaberriague L, Vikingstad EM, Levine SR, Welch KMA. Pilot study of functional MRI to assess cerebral activation of motor function after poststroke hemiparesis. *Stroke* 1998;29:112–22.
- Levy CE, Nichols DS, Schmalbrock PM, Keller P, Chakeres DW. Functional MRI evidence of cortical reorganization in upper-limb stroke hemiplegia treated with constraint-induced movement therapy. *Am J Phys Med Rehabil* 2001;80:4–12.
- Oldfield RC. The assessment and analysis of handedness: the Edinburgh Inventory. *Neuropsychologia* 1971;9:97–113.
- Cramer SC, Nelles G, Schaechter JD, Kaplan JD, Finklestein SP. Computerized measurement of motor performance after stroke. *Stroke* 1997;28:2162–8.
- Fugl-Meyer AR, Jaasko L, Leyman I, Olsson S, Steglind S. The post-stroke hemiplegic patient: a method for the evaluation of physical performance. *Scand J Rehabil Med* 1975;7:13–31.
- Wolf SL, LeCraw DE, Barton LA, Jann BB. Forced use of hemiplegic upper extremities to reverse the effect of learned nonuse among chronic stroke and head-injured patients. *Exp Neurol* 1989;104:125–32.
- Jiang A, Kennedy DN, Baker JR, et al. Motion detection and correction in functional MR imaging. *Hum Brain Mapp* 1995;3:224–35.
- Cohen MS, Bookheimer SY. Localization of brain function using magnetic resonance imaging. *Trends Neurosci* 1994;17:268–77.
- Talairach J, Tournoux P. *Co-planar stereotaxic atlas of the human brain*. Stuttgart, Germany: Thieme Medical Publishers; 1988.
- Duvernoy HM. *The human brain: surface, three-dimensional sectional anatomy and MRI*. New York: Springer-Verlag; 1991.
- Gati JS, Menon RS, Ugurbil K, Rutt BK. Experimental determination of the BOLD field strength dependence in vessels and tissue. *Magn Reson Med* 1997;38:296–302.
- Forman SD, Cohen JD, Fitzgerald M, Eddy WF, Mintum MA, Noll DC. Improved assessment of significant activation in functional magnetic resonance imaging (fMRI): use of a cluster-size threshold. *Magn Reson Med* 1995;33:636–47.
- Xiong J, Gao J-H, Lancaster JL, Fox PT. Clustered pixels analysis for functional MRI activation studies of the human brain. *Hum Brain Mapp* 1995;3:287–301.
- Liepert J, Miltner WH, Bauder H, et al. Motor cortex plasticity during constraint-induced movement therapy in stroke patients. *Neurosci Lett* 1998;250:5–8.
- Liepert J, Bauder H, Miltner WHR, Taub E, Weiller C. Treatment-induced cortical reorganization after stroke in humans. *Stroke* 2000;31:1210–6.
- Calautti C, Leroy F, Guincestre JY, Marie RM, Baron JC. Sequential activation brain mapping after subcortical stroke: changes in hemispheric balance and recovery. *Neuroreport* 2001;12:3883–6.
- Weiller C, Ramsay SC, Wise RJS, Friston KJ, Frackowiak RSJ. Individual patterns of functional reorganization in the human cerebral cortex after capsular infarction. *Ann Neurol* 1993;33:181–9.
- Wittenberg GF, Bastian AJ, Dromerick AW, Thach WT, Powers WJ. Mirror movements complicate interpretation of cerebral activation changes during recovery from subcortical infarction. *Neurorehabil Neural Repair* 2000;14:213–21.
- VanMeter JW, Maisog JM, Zeffiro TA, Hallett M, Herscovitch P, Rapoport SI. Parametric analysis of functional neuroimages: application to a variable-rate motor task. *Neuroimage* 1995;2:273–83.
- Rao SM, Bandettini PA, Binder JR, et al. Relationship between finger movement rate and functional magnetic resonance signal change in human primary motor cortex. *J Cereb Blood Flow Metab* 1996;16:1250–4.
- Sadato N, Ibanez V, Deiber MP, Campbell G, Leonardo M, Hallett M. Frequency-dependent changes of regional cerebral blood flow during finger movements. *J Cereb Blood Flow Metab* 1996;16:23–33.
- Waldvogel D, van Gelderen P, Kenji I, Hallett M. The effect of movement amplitude on activation in functional magnetic resonance imaging studies. *J Cereb Blood Flow Metab* 1999;19:1209–12.
- Dettmers C, Fink GR, Lemon RN, et al. Relation between cerebral activity and force in the motor areas of the human brain. *J Neurophysiol* 1995;74:802–15.

34. Wexler BE, Fulbright RK, Lacadie CM, et al. An fMRI study of the human cortical motor system response in increasing functional demands. *Magn Reson Imaging* 1997;15:385–96.
35. Thickbroom GW, Phillips BA, Morris I, Byrnes ML, Mastaglia FL. Isometric force-related activity in sensorimotor cortex measured with functional MRI. *Exp Brain Res* 1998;121:59–64.
36. Cramer SC, Weisskoff R, Schaechter JD, et al. Motor cortex activation is related to force of squeezing. *Hum Brain Mapp* 2002;16:197–205.
37. Cramer SC, Nelles G, Schaechter JD, Kaplan JD, Finklestein SP, Rosen BR. A functional MRI study of three motor tasks in the evaluation of stroke recovery. *Neurorehabil Neural Repair* 2001;15:1–8.
38. Wasserman EM, Pascual-Leone A, Hallett M. Cortical motor representation of the ipsilateral hand and arm. *Exp Brain Res* 1994;100:121–32.
39. Ziemann U, Borgheresi A, Yaseen Z, et al. Dissociation of the pathways mediating ipsilateral and contralateral motor-evoked potentials in human hand and arm muscles. *J Physiol* 1999;518:895–906.
40. Kopp B, Kunkel A, Muhlneckel W, Villringer K, Taub E, Flor H. Plasticity in the motor system related to therapy-induced improvement of movement after stroke. *Neuroreport* 1999;10:807–10.
41. Chen R, Gerloff G, Hallett M, Cohen LG. Involvement of the ipsilateral motor cortex in finger movements of different complexities. *Ann Neurol* 1997;41:247–54.
42. Schluter ND, Rushworth MFS, Passingham RE, Mills KR. Temporary interference in human premotor cortex suggests dominance for the selection of movements: a study using transcranial magnetic stimulation. *Brain* 1998;121:785–99.
43. Ehrsson HH, Fagergren A, Jonsson T, Westling G, Johansson RS, Forssberg H. Cortical activity in precision-versus power-grip tasks: an fMRI study. *J Neurophysiol* 2000;83:528–36.
44. Ferbert A, Priori A, Rothwell JC, Day BL, Colebatch JG, Marsden CD. Interhemispheric inhibition of the human motor cortex. *J Physiol* 1992;453:525–46.
45. Allison JD, Meador KJ, Loring DW, Figueroa RE, Wright JC. Functional MRI cerebral activation and deactivation during finger movement. *Neurology* 2000;54:135–42.
46. Weiller C, Chollet F, Friston KJ, Wise RJS, Frackowiak RSJ. Functional reorganization of the brain in recovery from striatocapsular infarction in man. *Ann Neurol* 1992;31:463–72.
47. Caramia MD, Palmieri MG, Giacomini P, Iani C, Dally L, Silvestrini M. Ipsilateral activation of the unaffected motor cortex in patients with hemiparetic stroke. *Clin Neurophysiol* 2000;111:1990–6.
48. Jones TA, Schallert T. Use-dependent growth of pyramidal neurons after neocortical damage. *J Neurosci* 1994;14:2140–52.
49. Stroemer RP, Kent TA, Hulsebosch CE. Neocortical neural sprouting, synaptogenesis, and behavioral recovery after neocortical infarction in rats. *Stroke* 1995;26:2135–44.
50. Jones TA, Chu CJ, Grande LA, Gregory AD. Motor skills training enhances lesion-induced structural plasticity in the motor cortex of adult rats. *J Neurosci* 1999;19:10153–63.
51. Biernaskie J, Corbett D. Enriched rehabilitative training promotes improved forelimb motor function and enhanced dendritic growth after focal ischemic injury. *J Neurosci* 2001;21:5272–80.